

EFFECT OF CLOMIPHENE CITRATE ON SOME ASPECT OF REPRODUCTIVE SYSTEM IN MATURE FEMALE RABBITS

Maesem Hassan Ali

*Physiological Dept. - College of Veterinary Medicine - University of Basrah .
Maesemhasan@yahoo.com

ABSTRACT

The effect of clomiphene citrate on the hormones, ovary and endometrium were studied in mature female rabbits treated with 10mg/kg twice daily for 20 days. Results cleared that there were a significant ($p < 0.05$) increase in the follicle stimulation hormone (FSH), estrogen and progesterone concentration, while, no significant changes were noticed in luteinizing (LH) and testosterone concentration. The most pronounced changes in reproductive system of female rabbits were found in the corpus luteum and filled with vacuolated cell, as well as endometrial hyperplasia occur. On the other hand gross section showed multi follicular (different numbers) on the right and left ovaries of female rabbits.

Key word: clomiphene citrate, hormones, histopathology, female rabbits.

INTRODUCTION

Clomiphene citrate (CC) is a synthetic non steroidal drug that acts on an anti estrogen and competitively binds to estrogen receptors in the hypothalamus and pituitary glands (Safeer *et al.* 2009). It is a combination with human chorionic gonadotrophin (HCG), human menopausal gonadotrophin (HMG) and sometime with FSH and LH (Pirrie and West, 1988). Clomiphene has also been shown to sensitize pituitary gonadotrophins to LHRH action both *in vivo* and *in vitro*, thus causing an excess secretion of FSH and LH in response to LHRH (Hsuch *et al.*, 1978; Schultz *et al.*, 1973). Moreover some reports indicated that clomiphene citrate has changed in the physiological action of estrogens and influences on the tissues of ovary that sensitive to estrogens signaling in female reproductive tissues, including rodent ovary (Chaube *et al.*, 2006) and human endometrium (Homburg *et al.*, 2006). Also (CC) has some side effects like as ovarian hyper stimulation, enlarged ovaries, thick cervical mucus, abdominal pain and hair loss (Fritz *et al.*, 1991) also a physiological or corpora lutea cyst (David and Tourgerman, 1988).

This study aimed to detect the effect of long period administration of clomiphene citrate treatment on LH, FSH, estrogen, progesterone and testosterone hormones, in addition the histological picture of ovary and uterus in mature female rabbits.

Received for publication Jan. 8, 2012 .

Accepted for publication May 20, 2012 .

MATERIALS AND METHODS

Twelve adult female rabbits, with mean body weight of 2 -2.5 kg were housed at the animal house of the Basrah College of Veterinary Medicine during winter season under the same conditions of room temperature . Each two animals were housed in one cage under normal periods of light/dark with free access of food and water . They were randomly divided into two experimental groups of six animals for each. First group was severed as controls and 2nd group received orally clomiphene citrate (10mg/kg) through stomach tube twice daily for 20 days. Treated and control rabbits were scarified on day 21 after the last dose. Blood sample (1.5 ml)were collected in vaccutainer tubes without any coagulant agents and immediately centrifuged to get serum which were frozen at -20 C° for hormonal analysis by using radio immuno assay kit . Spacemen from ovaries and uterus collected for gross and histological study .The ovaries of each animal were dehydrated progressively in ascending ethanol concentration, then treated with xylene and embedded in paraffin. Five micron thick section of paraffin embedded tissue were mounted on glass and stained with heamatoxylin and eosin stain . section were examined by mean of light microscope (Luna, 1993).

RESULT AND DISSCUSSION

Results of this study demonstrated the effect of drenching clomiphene citrate at a dose of 10mg/ kg body weight to mature female rabbits . Figure (1) indicates that there are significant increase ($p < 0.05$) in the estrogen , progesterone and FSH hormones concentrations of treated female rabbits as compared with control. These results are similar to those found by Fritz *et al* . (1991) ; Haritha and Rajiagopalan (2003)in women . Same trends were found by Chaube *et al*.(2005) ; Killic- okman *et al* .(2003),but our result are on the contrary of those found by Asimina *et al* . (2002)in respect to the above mentioned hormones, but testosterone concentration found in this study which is not significantly increased in treated female rabbits which disagreed with concentration found by Chuni (2007). Histological sections of ovaries , uterus and uterine tube of 21 days treated female rabbits shows advanced stages of vaculated lutenization of ovulated ovaries , endometrial hyperplasia and thickening of muscular wall of uterine tube pictures (1,2,3,5) these results are similar to those recognized by Clark and McCormack (1977) whose found that injection of clomid to rats causes multiple abnormalities of the reproductive tract . Also similar result was found by Stefan *et al*.(2006).

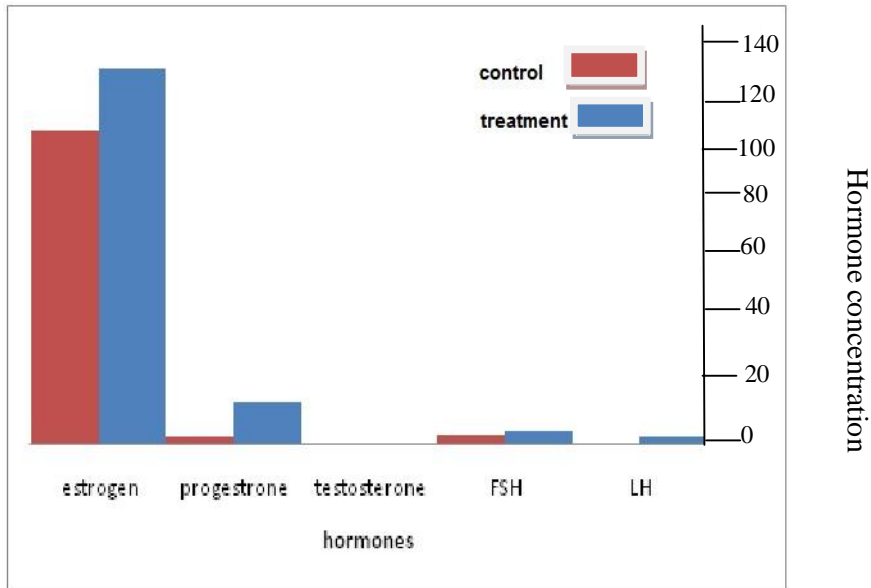
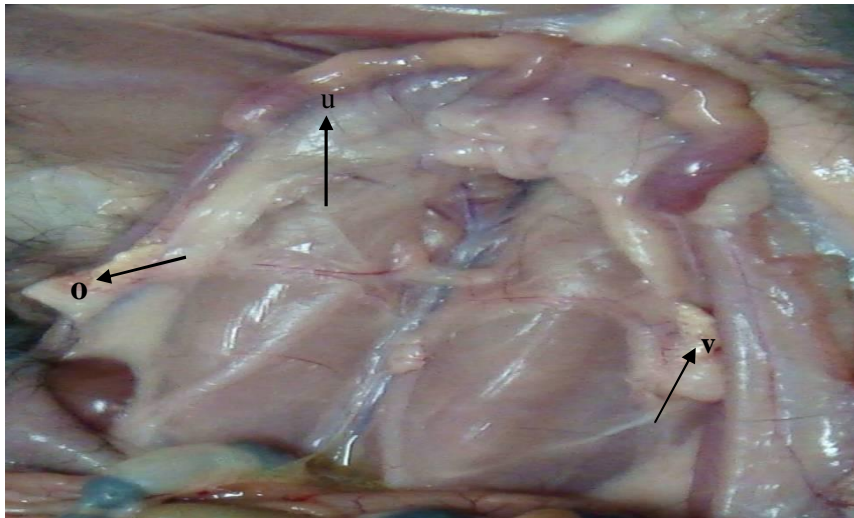
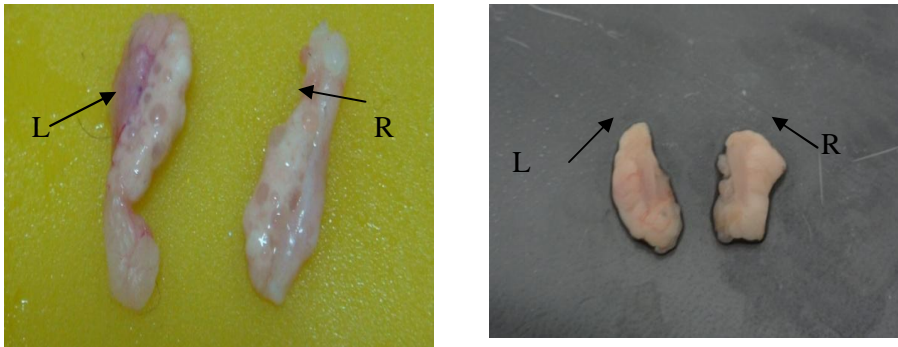


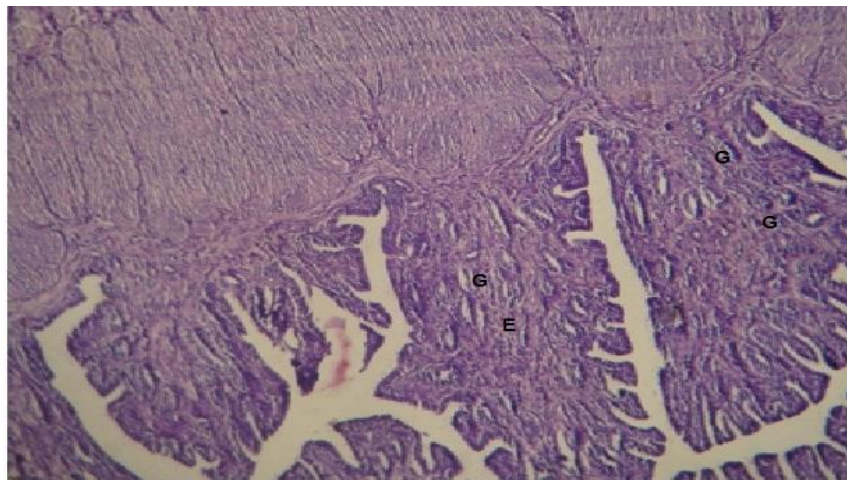
Fig .1. *Effect of superovulation on hormones in female rabbit by clomiphene citrate.*



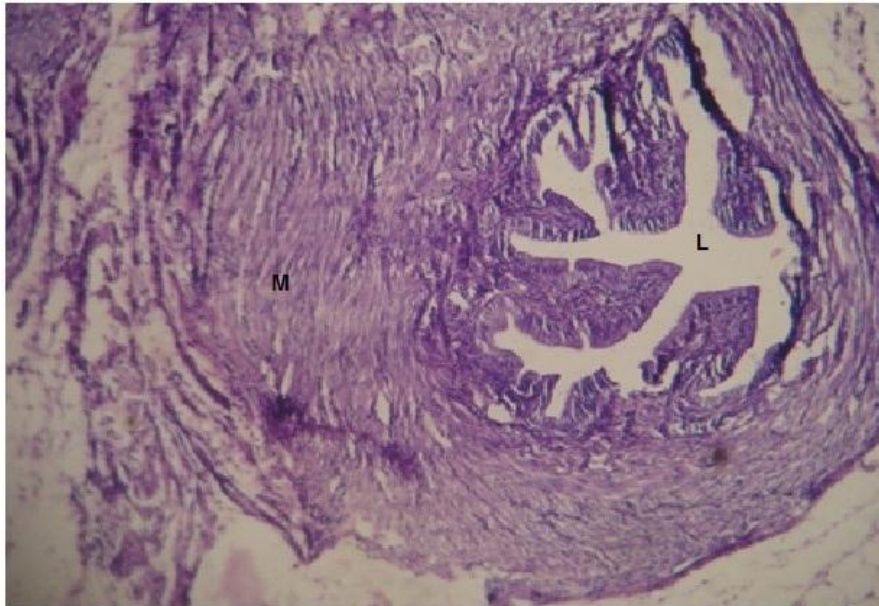
Picture 1. *Reproductive organs of the female rabbit showing ovaries(o), uterine horns(u) and part of the vagina(v) during treatment with clomiphene citrate.*



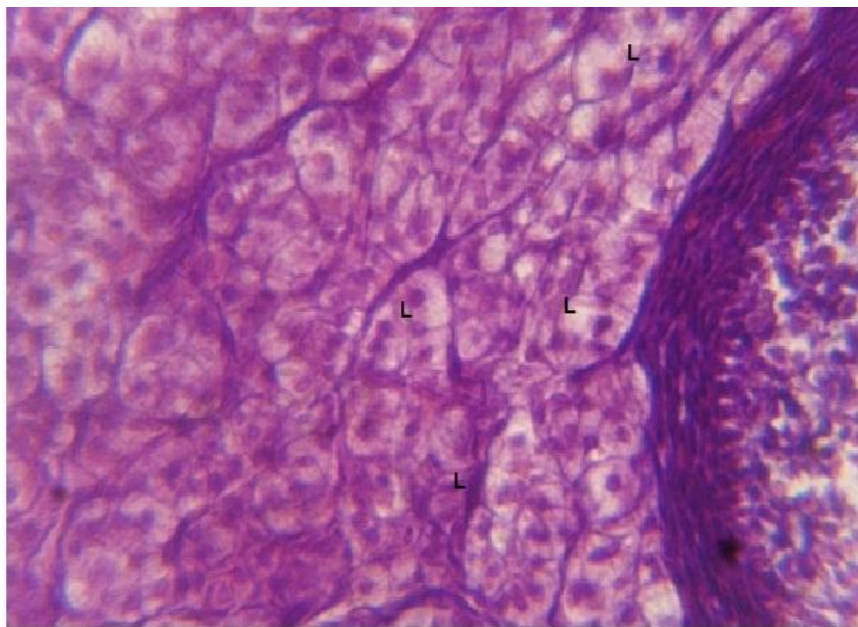
Picture 2 .Shows the difference in size and number of follicles of treated ovaries right (R)and left(L) compared to control ones.



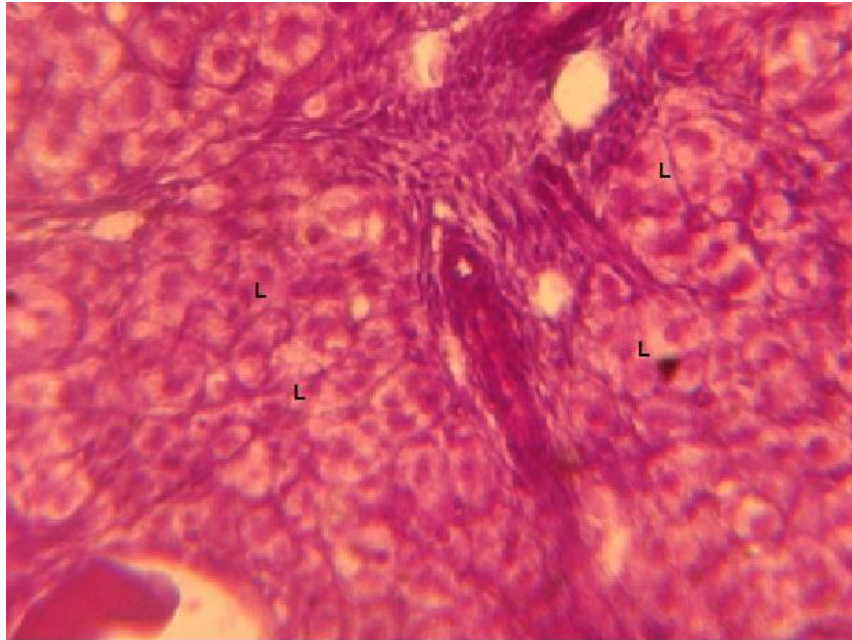
Picture 3 .Show endometrial hyperplasia (E) and increased thickness of sub epithelial endometrial glands (G) also there is hyperplasia of muscular wall .H&E stain (40x).



Picture 4. Section of fallopian tube shows clear thickening in muscular wall and narrowing of lumen (L) .H&E stain (10x).



Picture 5. Section of ovary shows clear vacuolated luteinizing cells of corpus luteum (L).H &E stain (100x).



Picture 6. Shows high magnification of corpus luteum of ovary indicated several stages of formation of luteal tissue (L) .H&E stain(40x).

REFERENCES

- Asimina, T., A. Carola , S. Johan and D. Paul .2002. Effect of clomiphene citrate on follicular and luteal phase luteinizing hormone concentration in vitro fertilization cycles stimulated with gonadotropins and gonadotropin-releasing hormone antagonist. *Fertility and Sterility* .77:733-737 .
- Chaube, S.K., P. V. Prasad, S. C. Thankur and T. G. Shrivastav. 2005. Estradiol protects clomiphene citrate induced apoptosis in ovarian follicular cells and ovulated cumulus –oocyte complexes . *Fertil . Steril* .84(2):1163-1172.
- Chaube, S. K., P.V. Prasad, V. Tripathi and T.G. Shrivastav. 2006.Clomiphene citrate inhibits gonadotrophins –induced ovulation by reducing cyclic adenosine 3,5-cyclic monophosphate and prostaglandin E2 levels in rat ovary.*Fertil.Steril*.86(4):1106-1111.
- Chuni, N. 2007.Efficacy of sequential treatment of metformin and clomiphene citrate in clomiphene resistant women with poly cystic ovary syndrome .*J.Obstet.Gynecol.India*.57(1):69-72.
- Clark, J.H. and S. McCormack.1977.Clomide or nafoxidine administered to neonatal rat causes reproductive tract abnormalities .*Science* .197(4299):164-165.
- David , E. and M.D. Tourgerman .1988. Alternatives for ovulation induction and superovulation :serms and aromatase inhibitors. *Reproductive Endocrinology and Infertility* . 29:173-175.

- Fritz, M. A., R.T . Holmes and E.J. Keenan .1991.Effect of clomiphene citrate treatment on endometrial estrogen and progesterone receptor induction in women . *Am.J. Obsret.Gynecol.*165:177-3
- Haritha ,S. and G. Rajiagopalan .2003. Follicular growth , endometrial thickness and serum estradiol level in spontaneous and clomiphene citrate – induced cycles . *Int. J. Gynecol . Obstet .* 81:287-292.
- Homburg , R., H. Pap, M. Brandes, J. Huime , P. Hompes and C.B. Lambalk.2006..Endometrial biopsy during induction of ovulation with clomiphene citrate in polycystic ovary syndrome.*Gynecol Endocrinal* .22:506-510.
- Hsuch , A.J.W., G.F. Erickson and S.S.C.Yen .1978. Sensitization of pituitary cells to luteinizing hormone releasing hormone by clomiphene citrate in vitro.*Nature* .273:57-59.
- Killic-okman, T., M. Kucuk and S. Altaner .2003. Comparison of the effect of letrozole and clomiphene citrate on ovarian follicles , endometrium and hormone leveling the rat.*Fertil .Steril* .80:1330-1332.
- Luna , L. G. 1993. *Manual of histology staining methods of armed forces institute of pathology* .4th ed . Lange Medical Printer. UK; 65-78.
- Pirrie , M. and R. West .1988.Vasectomy make,IVF surrogate infertility ,Says QG. The Age , Melbourne, April 16.1271.
- Safeer , Z., Z . Sibgha and M. Shoaibkhan .2009. Evaluation of effects of clomiphene citrate on serum testosterone and FSH levels and seminal parameters in idiopathic oligospermia .*Bio. Medica* .25:48-51.
- Schultz ,K.D., S. August , B. Wustenberg and F. Holzel .1973.Oestrogen- like and anti estrogenic potencies of clomiphene citrate :Biochemical investigation .In: Fertility and Sterility (T.Hasegawa, M. Hayashi ,F.J. Ebling and I.W, Hendesson ,eds) .*Excerpta Medica ,Amsterdam* :642-645.
- Stefan ,P., R. Tiziana , O.J .Francesco , F. Angela , M. Francesco , S. Annalidia ,T. Achille ,C. Annamaria ,C. Enrico and Z. Fulvio 2006.Uterin effects of clomiphene citrate in women with polycystic ovary syndrom: a prospective conterolled study, *Human Reproduction*. Vol ,21 , p, 2823-2829.

دراسة تأثير عقار كلوميفين سترات على بعض جوانب الجهاز التناسلي في إناث الأرانب الناضجة .

ميسم حسن علي

*مدرس مساعد - فرع الفسلجة - كلية الطب البيطري - جامعة البصرة . Maesemhasan@yahoo.com

المستخلص

تمت دراسة تأثير عقار كلوميفين سترات على المبيض وبطانة الرحم وهرمونات الإناث الناضجة للأرانب التي عوملت بـ ١٠ ملغم/كغم مرتين يوميا لمدة ٢٠ يوم. أظهرت نتائج هذه الدراسة زيادة معنوية ($p < 0.05$) في تركيز هرمون المنبه للمبيض (FSH) وهرمون الاستروجين وهرمون البروجيستيرون ولم تلاحظ أي زيادة معنوية في تركيز هرمون (LH) و التيستيرون. التغيرات النسيجية الأكثر وضوحا كانت في الجسم الأصفر الذي أمتلئ بالخلايا الفقاعية وكذلك لوحظ تضخم بطانة الرحم في إناث الأرانب . من ناحية أخرى أظهرت المقاطع العيانية تعدد الجر بيات (أعداد مختلفة) على المبيضين الأيمن والأيسر للإناث الناضجة .

الكلمات المفتاحية : كلوميفين سترات ،هرمونات، التشريح المرضي، إناث الأرانب .